



ASE

AMERICAN SOCIETY OF
ECHOCARDIOGRAPHY

Sound Saves Lives

Specific Considerations for Pediatric, Fetal, and Congenital Heart Disease Patients and Echocardiography Service Providers During the 2019 Novel Coronavirus Outbreak: Council on Pediatric and Congenital Heart Disease Supplement to the Statement of the American Society of Echocardiography

Endorsed by the Society of Pediatric Echocardiography and the Fetal Heart Society

© 2020 American Society of Echocardiography

Piers C.A. Barker, MD, FASE (Chair), Mark B. Lewin, MD, FASE, Mary T. Donofrio, MD, FASE, Carolyn A. Altman, MD, FASE, Gregory J. Ensing, MD, FASE, Bhawna Arya, MD, FASE, Madhav Swaminathan, MD, FASE, *Durham, North Carolina; Seattle, Washington; Washington, District of Columbia; Houston, Texas; Ann Arbor, Michigan.*

From Duke University, Durham, North Carolina (P.B. and M.S.); University of Washington/Seattle Children's Hospital, Seattle, Washington (M.L. and B.A.); Children's National Hospital, Washington, District of Columbia (M.D.); Baylor College of Medicine/Texas Children's Hospital, Houston, Texas (C.A.); University of Michigan/C.S. Mott Children's Hospital, Ann Arbor, Michigan (G.E.).

The authors reported no actual or potential conflicts of interest in relation to this document.

Notice and Disclaimer: This statement reflects recommendations based on expert opinion, national guidelines, and available evidence. Our knowledge with regard to COVID-19 continues to evolve, as do our institutional protocols for dealing with invasive and non-invasive procedures and practice of personal protective equipment. Readers are urged to follow national guidelines and their institutional recommendations regarding best practices to protect their patients and themselves. These reports are made available by ASE as a courtesy reference source for its members. The reports contain recommendations only and should not be used as the sole basis to make medical practice decisions or for disciplinary action against any employee. The statements and recommendations contained in these reports are primarily based on the opinions of experts, rather than on scientifically-verified data. ASE makes no express or implied warranties regarding the completeness or accuracy of the information in these reports, including the warranty of merchantability or fitness for a particular purpose. In no event shall ASE be liable to you, your patients, or any other third parties for any decision made or action taken by you or such other parties in reliance on this information. Nor does your use of this information constitute the offering of medical advice by ASE or create any physician-patient relationship between ASE and your patients or anyone else.

Background

The American Society of Echocardiography has recently released a statement on the “Protection of Patients and Echocardiography Service Providers During the 2019 Novel Coronavirus Outbreak” which will be continually updated as more data become available.¹ The pediatric and congenital heart disease (PCHD) population adds a confounding variable to this pandemic, which this supplement to the main statement¹ means to address. Readers are recommended to review the main statement;¹ this supplement will discuss how the PCHD population is different from the adult population, including transmission risk and indications for echocardiography; variations in protocols; and recommendations for fetal echocardiography and transesophageal echocardiography (TEE) for the PCHD population.

Although children as an entire group appear to be at lower risk for severe disease compared to adults, certain ages are more susceptible to severe disease than others (particularly infants and pre-school aged children, and possibly premature infants).² The overall lower prevalence of severe disease paradoxically means that a large number of infected children may be asymptomatic or minimally symptomatic.^{2,3} When combined with the high viral loads present in nasopharyngeal and fecal secretions,^{4,5} frequency of other upper respiratory tract viral co-infections,³ necessity of adults accompanying children to medical care, and limited capabilities to avoid droplet expression in infants and toddlers, echocardiographic scanning of children may create an increased risk of staff and community exposure. Consequently, PCHD echocardiography providers will be exposed to SARS-CoV-2, perhaps often unknowingly, requiring adjustments in practice to provide expert care and limit further community transmission.

Indications for the use of echocardiography in the PCHD population also differ from the adult population.⁶ For PCHD patients, echocardiography will remain critical for the assessment of children with suspected heart disease, management of children and young adults with acquired and congenital heart disease at different stages of repair, palliation or transplant, and children at risk of functional heart disease (e.g. receiving chemotherapy) or cardiac complications from respiratory infection. Fetal and transesophageal echocardiography represent important clinical scenarios requiring variations in management. Pregnancies will continue and fetal heart disease remains critical to diagnosis and manage, albeit while reducing risk for infection of the mother or provider. Avoidance of provider transmission to the premature infant population with lung disease of different etiologies is similarly critical.

Whom to image?

Review of Indications

As a general principle, transthoracic echocardiograms (TTE), stress echocardiograms, transesophageal echocardiograms (TEE), and fetal echocardiograms should only be performed if they are expected to provide clinical benefit. Decisions on whether or not an echocardiogram

should be performed in a PCHD patient may be guided by the appropriate use criteria established by the ASE and other societies,^{7,8} with risk of SARS-CoV-2 infection highlighting the need to avoid rarely appropriate exams. In addition, multiple societies (AIUM, ISUOG and AHA) have established guidelines for indications for fetal echocardiography referral. A full discussion of how to determine both *who* should be imaged as well as *when* imaging should be considered is presented in the main statement,¹ acknowledging that adjustments to these decisions should be made by each individual institution.

Fetal echocardiographic evaluation presents different challenges; there is a finite gestational period within which pregnancy decision-making and perinatal/neonatal management plans are made. The AHA divides fetal echocardiography referrals into risk levels based on indication.⁹ Triage and scheduling of these patients in general can be determined based on an assessment of level of risk relating to the indication for referral as well as the fetal diagnosis. TEE carries a heightened risk of spread of SARS-CoV-2 since it can provoke aerosolization of a large amount of virus. Whether the intubated PCHD patient having a TEE exposes the care team to a greater risk with this modality compared to TTE remains unclear. Considerations for both fetal echocardiography and PCHD TEE are discussed in greater detail in the Advanced Imaging section below.

Where to image?

The increased possibility that children may be infected with no or minimal symptoms may limit the utility of adult-focused screening measures. This may then necessitate adjustments to both inpatient and outpatient procedures such as designating which studies should be performed as portable studies, or designation of specific echo lab scan rooms or outpatient clinic sites. Given the higher risk of asymptomatic transmission in children, some centers in endemic regions are also choosing to test all new pediatric admissions for SARS-CoV-2.

For institutions where fetal imaging occurs within the cardiology clinic, consideration should be given for pregnant women to be sequestered in a separate area from the pediatric patients, both in the waiting room and echo lab. Unlike previous viral outbreaks (H1N1, SARS-CoV, MERS-CoV) which were found to be associated with severe complications in pregnant women, currently the limited information available suggests that pregnant women are not more susceptible to SARS-CoV-2 infection or more prone to developing severe complications if infected.¹⁰ Given the uncertainty and possibility of increased risk as more data become available, the CDC cautions that it is always important for pregnant women to protect themselves from illnesses, though the current recommendation is for them to follow the same precautions as the general public to avoid infection. For fetal cardiology visits, a maximum of one support person who undergoes the same screening process as the patients may accompany the pregnant women to the visit; however to minimize exposure, the echocardiogram scanning room should be limited to the pregnant woman alone and sonographer. Counseling of the family should be limited to the pregnant woman and one support person at most, though if

possible having the support person be offsite and participate in the counseling session using telemedicine may be beneficial. Telemedicine consultation without fetal echocardiogram should be considered when the visit is limited to follow-up counseling of established fetal cardiovascular disease. If the fetal echocardiogram can be performed and then read remotely (e.g. for known CHD, SSA/SSB antibody or arrhythmia follow-up), telemedicine should be considered for relaying findings and performing counseling. This may be particularly useful if the fetal echocardiogram can be done in the Maternal-Fetal Medicine (MFM) office, where visits can be consolidated to include routine obstetrical care. Home fetal heart rate monitoring with telemedicine consultation instead of intermittent fetal echocardiography can also be considered in cases of fetal arrhythmia to minimize follow-up clinic visits.

How to image?

Protocols

Infants or children presenting with known or suspected congenital heart disease, cardiomyopathy or myocarditis may have intercurrent respiratory illnesses and thus may be under suspicion for SARS-CoV-2 infection. This will require modification of PCHD imaging protocols away from “complete” studies and towards more focused exams. However, the breadth of congenital heart disease, and the challenges of systolic and diastolic function assessment in the PCHD population mean that unless the patient is in immediate need of assessment of only systolic function or pericardial effusion, “traditional” TTE by cardiology (pediatric or ACHD) is preferred over point of care ultrasound (POCUS) in the pediatric emergency center or intensive care unit. If a POCUS exam is performed, images should be saved and archived in a manner that allows review and remote interpretive assistance from experienced pediatric echocardiographers as well as comparison of cardiac structure and function over time. Review of POCUS studies may also help focus future imaging studies.

Additional recommendations for focusing exams, particularly in patients with suspected or confirmed COVID-19, are presented in the main statement.¹ These include the use of live feeds and/or remote feedback to limit personnel in the patient room, and matching of sonographer skill to study indication to maximize diagnostic accuracy while minimizing scan time. As for adult patients, scans should be reviewed, and results recorded and communicated to the ordering team as quickly as possible to facilitate care.

For fetal echocardiographic studies, a complete study should be performed for all new consultations in order to minimize the need for repeat studies. Centers should have well-defined study protocols and checklists available as the study is being performed and as it is reviewed prior to the pregnant woman leaving the exam room. For follow-up scans deemed necessary, a focused study based on a predetermined checklist provided by the fetal cardiologist may be utilized. Prolonged scanning should be avoided. Transvaginal fetal echocardiographic studies should not be performed.

Protection

Imaging of the pediatric patient with possible or confirmed COVID-19 differs from imaging of the adult in several ways. Children may frequently be asymptomatic or minimally symptomatic, which may unknowingly expose the provider to infection. Children are often unable to cooperate and follow instructions; cardiac anatomy may be highly variable and require longer scan times to assess; and sedation may be necessary for even routine transthoracic studies. Thus protection procedures require modification to those recommended for general adult echocardiography as presented in the main statement.¹ These PCHD modifications are presented below. Additional information regarding the role of learners, options for echocardiography education in the absence of direct scanning, and important general considerations for reducing transmission outside of the scan room are presented in the main statement.¹

Personnel

As for the adult patient, imaging should be performed according to local standards for the prevention of virus spread, including use of Personal Protective Equipment (PPE). Meticulous and frequent hand washing is crucial and applies to the sonographer, patient when possible, and to a single caregiver who is likely to contact patient and sonographer while helping to facilitate the cooperation of an active child. A surgical face mask should be worn by symptomatic patients, provided appropriate pediatric and adult-sized masks are available and institutional resources allow this strategy for source control.¹¹ In addition to the aerosolized transmission of SARS-CoV-2, potential for fecal transmission has been reported.^{5,12} Diaper care should therefore be avoided if possible during the exam, and if necessary performed with appropriate virucidal hygiene.

The performance and interpretation of pediatric and fetal echocardiographic studies, especially those in suspected or confirmed COVID-19 cases, should be limited to essential personnel. Potentially complicated exams should be directed to experienced sonographers who are most likely to be able to perform an appropriately detailed, accurate, and expeditious exam without the need for additional hands-on support. In many institutions, PCHD fellows provide crucial off-hours scanning and interpretation, but their skill level should be matched to patient complexity with availability of additional imager expertise when an expeditious exam cannot be obtained. In addition to limiting the number of echocardiography practitioners involved in scanning, consideration should be given to limiting the exposure of staff who may be particularly susceptible to severe complications of COVID-19. Staff who are >60 years old, have chronic conditions, are immunocompromised or are pregnant may wish to avoid contact with patients suspected or confirmed to have COVID-19, depending on local procedures.

For intraoperative TEE, which is an essential contributor to the effective surgical treatment of congenital heart disease, strong consideration should be given to requesting that the anesthesiologist place the TEE probe immediately after airway intubation while using appropriate aerosol precautions. Probe removal should be performed while under deep general anesthesia while intubated, with the probe immediately cleaned and then placed in a transport

container for disinfection. There should be at most one person to handle the probe and another to operate the machine controls, along with another to administer anesthesia or sedation. Many pediatric echocardiographers are capable of simultaneously manipulating the TEE probe and operating the machine; this practice should be encouraged to reduce exposure of an additional provider, presuming skill with this technique and that use of this technique will not increase total scan time.

Equipment

Equipment care is critical in the prevention of SARS-CoV-2 transmission. Options to decrease fomite transmission may include covering probes and machine consoles with disposable plastic and foregoing the use of ECG stickers, or setting aside certain machines or probes for use on patients with suspected or confirmed infection. Similarly, setting aside a separate machine for sole use in expected high-risk groups such as the neonatal intensive care unit is encouraged when possible. Equipment cleaning should be performed according to institutional and vendor guidelines. Additional guidelines for the disinfection of ultrasound equipment are available through the AIUM.¹³ Smaller, laptop-sized portable machines are more easily cleaned, but use of these machines should be balanced against potential tradeoffs in image quality and functionality.

Advanced Imaging:

Fetal Echocardiography

Fetal echocardiography and the care of pregnant women require a separate triaging system, which can be divided into three subgroups (Table and Figure 1).

- Fetal echocardiogram for low risk patients: if a detailed second trimester fetal anatomic scan including adequate cardiac screening views can be confirmed by combined experience of practitioners (fetal cardiologist with Maternal-Fetal Medicine specialist/Obstetrician), no fetal echocardiographic evaluation is scheduled.
- Fetal echocardiogram for moderate risk patients: delay fetal echocardiography evaluation to a later date when SARS-CoV-2 risk is decreased or after 28 weeks gestation (or earlier in specific situations, described in more detail below).
- Fetal echocardiogram for high risk patients or urgent clinical indications: schedule and perform promptly (though consider alternatives such as lowest risk facility for imaging and telemedicine for consultation to minimize risk).

This triage system requires close communication with the referring Obstetrical and Maternal-Fetal Medicine teams; noting that the recommended algorithms presented are not evidence-based but do represent shared perceived best practices and can be modified by each institution to best match local resources. Once it is decided that a Fetal Cardiology visit is needed, the timing of the Fetal Cardiology visit is based on multiple factors: 1) the risk profile of the indication (see Table); 2) the adequacy of the anatomy scan with cardiac views (determined by local

collaborative experience of the referring doctor and fetal cardiologist, or if needed, direct review of the cardiac screen, or discussion with the referring doctor); 3) the gestational age of the fetus which influences both pregnancy decision-making and need for additional testing (e.g. amniocentesis, ultrasound, MRI, gestational age < 24 weeks) and delivery planning for fetal CHD (gestational age \geq 34 weeks). For those deferred to a later date, creation of a virtual “waiting list” should be considered for scheduling to assure that all patients at risk are evaluated prior to delivery. Fetal cardiovascular diseases requiring transplacental therapy (e.g. fetal tachyarrhythmia or autoimmune-mediated evolving congenital heart block) should be considered urgent indications for echocardiography and consultation, and scheduling and evaluating these patients should follow the admitting institutions COVID-19 policies for urgent admissions. Performance of fetal cardiac interventions (i.e. balloon aortic or pulmonary valvuloplasty, atrial septal stenting) remains at the discretion of the institution, though given the current body of evidence on risk-benefit ratio, delaying or not doing the procedure may be considered. The timing and performance of fetal interventions for twin-twin transfusion syndrome (TTTS) are beyond the scope of this document.

The possibility of prenatal or perinatal infection should be considered when neonates are transferred to the neonatal or pediatric cardiac intensive care unit following delivery. There is inconclusive data regarding vertical transmission of SARS-CoV-2; however, if a pregnant woman tests positive for the virus within 14 days of delivery, the newborn should be tested and treated as positive, with use of appropriate PPE, until a negative result is confirmed.

Transesophageal Echocardiography

Transesophageal echocardiography carries a heightened risk of spread of SARS-CoV-2 since aerosolization of virus may be provoked during the procedure. This is of particular concern if the TEE is performed without concomitant endotracheal intubation, due to the coughing or gagging that may accompany probe placement and manipulation. However, aerosolization and provider exposure may be possible even with an endotracheal tube in place due to the instrumentation and manipulation of the oropharynx that occurs with TEE probe placement. TEEs therefore deserve special consideration in determining when and whether they should be performed, and under what precautions. TEE should be considered an integral part of PCHD perioperative care or care during PCHD cardiac catheter interventions. Outside of these scenarios, TEE should be considered a high-risk procedure and the benefits of a TEE examination weighed against the risk of exposure of healthcare personnel in a patient with suspected or confirmed COVID-19 and the availability of PPE. TEEs should be postponed or canceled if an alternative imaging modality (e.g. off axis TTE views, agitated saline contrast or other ultrasound enhancing agent with TTE) can provide the necessary information. Contrast enhanced computed tomography (CT) and magnetic resonance imaging (MRI) may also be considered as alternatives to TEE. The benefits of avoiding an aerosolizing procedure should be balanced against the risk of transport, need to disinfect a different scan room, as well as the

baseline risks in children of iodinated contrast and radiation with CT, and longer scan times for MRI.

Given the unreliability of symptoms to predict COVID-19 status in children, use of a standardized algorithm for TEE procedures is recommended. An example is presented below and in Figure 2. Modification and implementation of any TEE algorithm should be coordinated with all members of the perioperative team at each institution to best match resources and equipment. Ideally, as SARS-CoV-2 testing becomes more available at the hospital level with more rapid resulting, all patients for whom TEE is planned (i.e. most surgical patients, and some interventional cardiac catheterization patients) should have SARS-CoV-2 testing performed during pre-op screening.

1. All pediatric patients for TEE are presumed positive unless they have had a negative COVID-19 test within 48 to 72 hours. **If documented negative COVID-19 testing, then TEE may proceed using standard precautions (gloves, mask, and eye protection).**
2. For **pediatric patients without COVID-19 negative testing within 72 hours who are intubated prior to arrival to the Cardiovascular Operating Room (CVOR)/interventional suite**, the risk for aerosolization is considered low. Probe placement may be performed by anesthesia to minimize personnel performing oropharyngeal manipulation or by cardiology according to institutional standard procedures and following standard precautions.
3. For **asymptomatic patients without COVID-19 negative testing within 72 hours who require intubation in the CVOR/interventional suite**, anesthesia should intubate donning appropriate PPE/Powered Air Purifying Respirators (PAPR). This should be followed by a wait period (typically 20-30-minutes depending on local protocols and environmental factors) to permit complete air turnover in the room, during which no one should enter. Strong consideration should be given to TEE probe placement by anesthesia immediately following airway stabilization while still under aerosol precautions and prior to the air turnover period to minimize the risk of exposure of additional personnel. After the wait period, probe manipulation may be performed by cardiology according to institutional standard procedures and following standard precautions.
4. For **COVID-19 positive or symptomatic children without COVID-19 negative testing within 72 hours**, strict isolation is mandated. Strong consideration should be given to probe placement by anesthesia to minimize risk of exposure associated with oropharyngeal manipulation and according to institutional standard procedures.
 - a. All personnel in the CVOR, interventional suite, or procedure room must wear strict isolation gear at all times.
 - b. All personnel must have training in donning and doffing PPE/PAPR
 - c. Only essential personnel in CVOR to preserve PPE and mitigate exposure risk (1 echo person only)

Conclusion

The provision of echocardiographic services to the PCHD population remains crucial during this SARS-CoV-2 outbreak. Differences between the adult and PCHD populations require modifications to prior practices. These PCHD modifications are summarized in Figure 3. Working together with our adult Cardiology, Anesthesia, Maternal-Fetal Medicine and Pediatric colleagues, we can continue to provide high quality care while minimizing risk to ourselves, our patients and the public.

Acknowledgements

This statement was prepared by Piers Barker, MD, Mark Lewin, MD, (representing the Society of Pediatric Echocardiography), Mary Donofrio, MD (representing the Fetal Heart Society), Carolyn Altman, MD, Gregory Ensing, MD, Bhawna Arya, MD, and Madhav Swaminathan, MD, and was approved by the American Society of Echocardiography executive committee on April 2, 2020.

Protocols and procedures used in the preparation of this document courtesy of the authors, Luciana Young, University of Washington/Seattle Children's Hospital, Seattle, WA (for the TEE algorithm) and many others through the COVID-19 Cardiology Listserv (Seattle Children's Hospital), Society of Pediatric Echocardiography discussion groups, and Fetal Heart Society Forum members discussion group.

References

1. Kirkpatrick JN, Mitchell C, Taub C, Kort S, Hung J, Swaminathan M. ASE Statement on Protection of Patients and Echocardiography Service Providers During the 2019 Novel Coronavirus Outbreak. *J Am Soc Echocardiogr* 2020; Article in Press. doi: 10.1016/j.echo.2020.04.001
2. Dong Y, Mo X, Hu Y, Qi X, Jiang F, Tong S. Epidemiological Characteristics of 2143 Pediatric Patients With 2019 Coronavirus Disease in China. *Pediatrics*. 2020; doi: 10.1542/peds.2020-0702
3. Cruz A, Zeichner S. COVID-19 in Children: Initial Characterization of the Pediatric Disease. *Pediatrics*. 2020; doi: 10.152/peds.2020-0834
4. Wölfel R, Corman V, Guggemos W, Seilmaier M, Zange S, Mueller M, et al. *Clinical presentation and virological assessment of hospitalized cases of coronavirus disease 2019 in a travel-associated transmission cluster*. MedRxiv 2020.03.05.20030502; doi: 10.1101/2020.03.05.20030502
5. Xiao F, Tang M, Zheng X, Liu Y, Li X, Shan H. Evidence for gastrointestinal infection of SARS-CoV-2. *Gastroenterology*. (2020); doi: 10.1053/j.gastro.2020.02.055
6. Zheng YY, Ma YT, Zhang JY, Xie X. COVID-19 and the cardiovascular system. *Nat Rev Cardiol*. (2020); doi: 10.1038/s41569-020-0360-5
7. Campbell RM, Douglas PS, Eidem BW, Lai WW, Lopez L, Sachdeva R. ACC/AAP/AHA/ASE/HRS/SCAI/SCCT/SCMR/SOPE 2014 appropriate use criteria for initial transthoracic echocardiography in outpatient pediatric cardiology: a report of the American College of Cardiology Appropriate Use Criteria Task Force, American Academy of Pediatrics, American Heart Association, American Society of Echocardiography, Heart Rhythm Society, Society for Cardiovascular Angiography and Interventions, Society of Cardiovascular Computed Tomography, Society for Cardiovascular Magnetic Resonance, and Society of Pediatric Echocardiography. *J Am Soc Echocardiogr*. 2014;27(12):1247-1266.
8. Sachdeva R, Valente AM, Armstrong AK, Cook SC, Han BK, Lopez L, et al. ACC/AHA/ASE/HRS/ISACHD/SCAI/SCCT/SCMR/SOPE 2020 Appropriate Use Criteria for Multimodality Imaging During the Follow-Up Care of Patients With Congenital Heart Disease: A Report of the American College of Cardiology Solution Set Oversight Committee and Appropriate Use Criteria Task Force, American Heart Association, American Society of Echocardiography, Heart Rhythm Society, International Society for Adult Congenital Heart Disease, Society for Cardiovascular Angiography and Interventions, Society of Cardiovascular Computed Tomography, Society for Cardiovascular Magnetic Resonance, and Society of Pediatric Echocardiography. *J Am Coll Cardiol*. 2020;75(6):657-703.

9. Donofrio MT, Moon-Grady AJ, Hornberger LK, Copel JA, Sklansky MS, Abuhamad A, et al. Diagnosis and treatment of fetal cardiac disease: a scientific statement from the American Heart Association. *Circulation*. 2014;129(21):2183-2242.
10. Poon LC, Yang H, Lee JCS, Copel JA, Leung TY, Zhang Y, et al. (2020) ISUOG Interim Guidance on 2019 novel coronavirus infection during pregnancy and puerperium: information for healthcare professionals. *Ultrasound Obstet Gynecol*. 2020 doi: 10.1002/uog.22013.
11. CDC. Strategies for Optimizing the Supply of Facemasks. <https://www.cdc.gov/coronavirus/2019-ncov/hcp/ppe-strategy/face-masks.html>. Published 2020. Accessed March 20, 2020.
12. Gu J, Han B, Wang J. COVID-19: Gastrointestinal manifestations and potential fecal-oral transmission. *Gastroenterology*. (2020) doi: [10.1053/j.gastro.2020.02.054](https://doi.org/10.1053/j.gastro.2020.02.054).
13. AIUM. Guidelines for Cleaning and Preparing External- and Internal-Use Ultrasound Transducers Between Patients & Safe Handling and Use of Ultrasound Coupling Gel. [https://www.aium.org/officialStatements/57\[aium.org\]](https://www.aium.org/officialStatements/57[aium.org]). Published 2020. Accessed March 28, 2020.

Figure 1

Fetal Cardiology Clinic Scheduling Algorithm during COVID-19 Outbreak

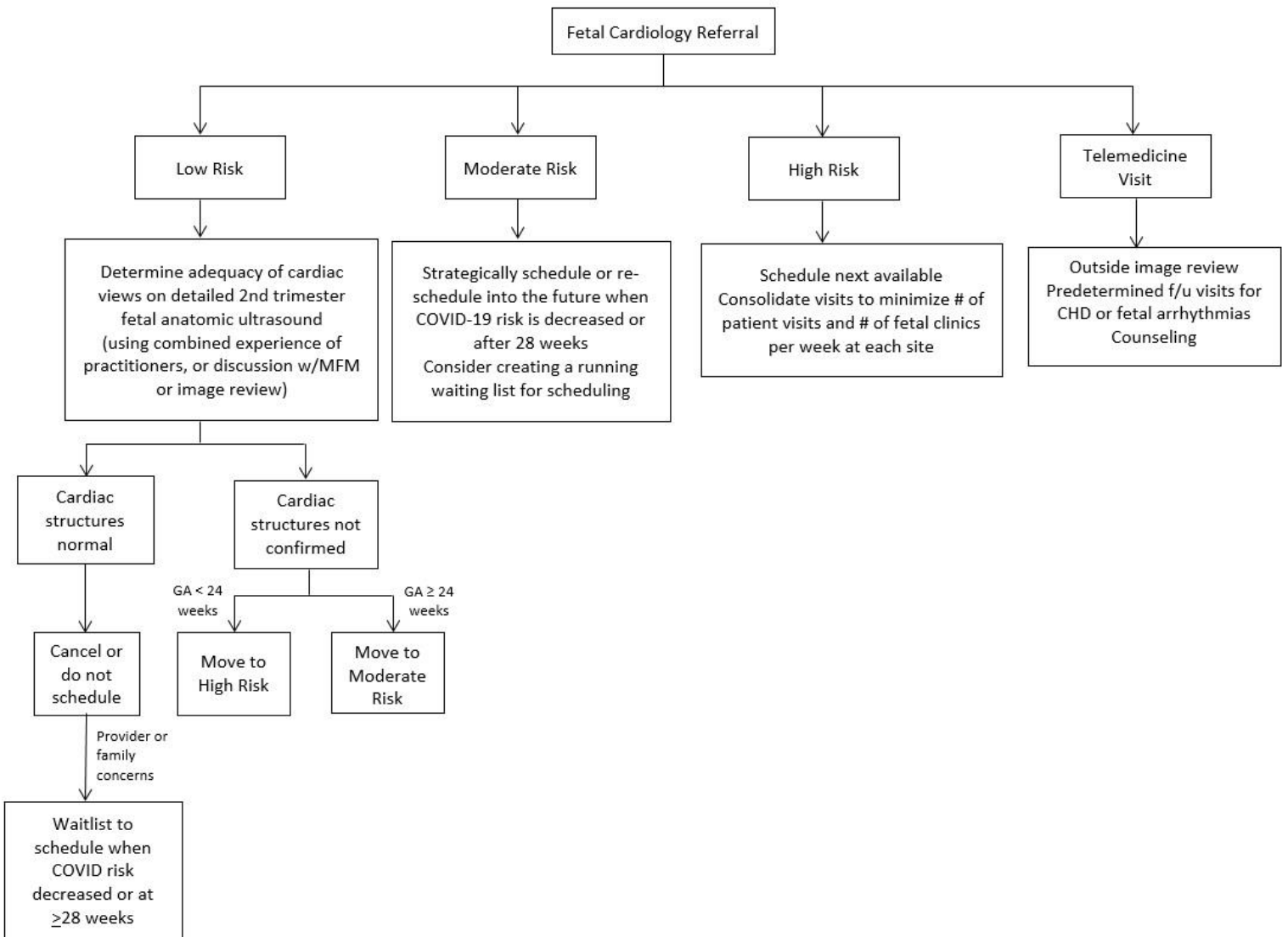


Figure 2

Suggested algorithm for performing TEE during COVID-19 Outbreak

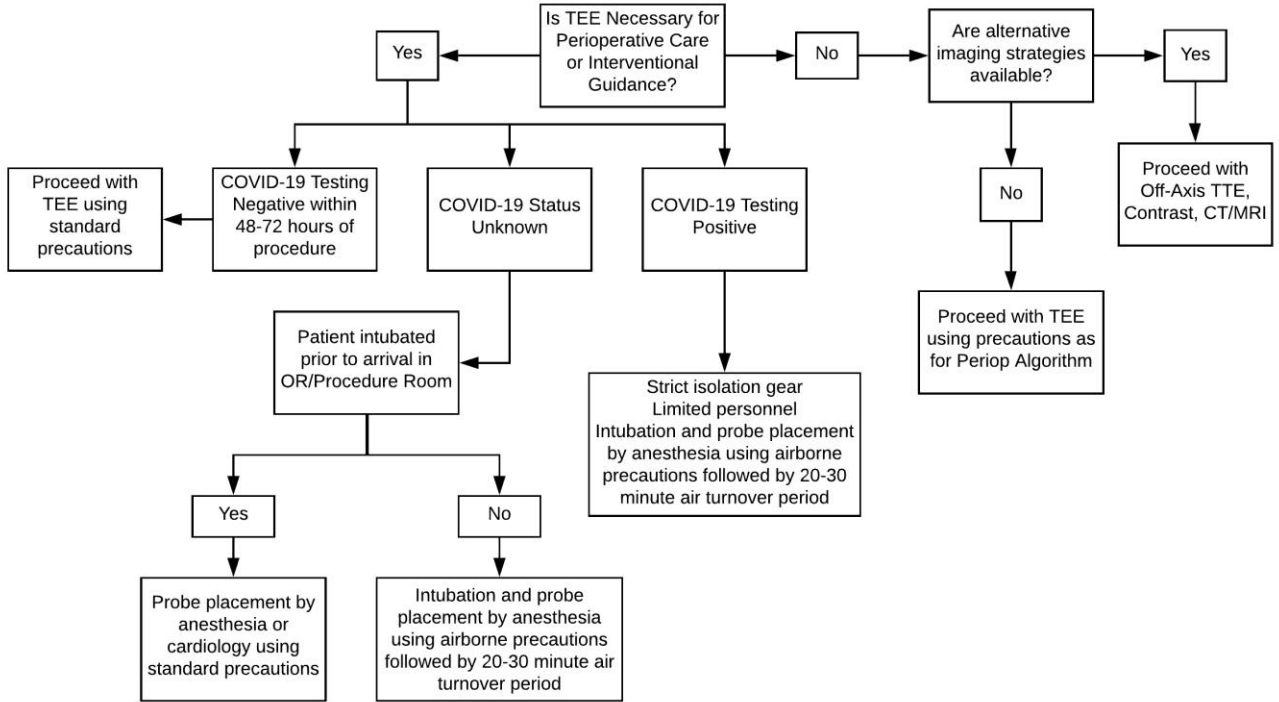


Figure 3

Summary of Recommendations for Policies/Procedures during COVID-19 Outbreak

- Defer/Reschedule Options
 - Identify and defer all elective exams
 - Identify and perform only urgent/emergency exams
 - Assess need for fetal echocardiogram and schedule using algorithm
- Assess patient COVID-19 status
 - Negative
 - Suspected
 - Unknown (for TEE, treat as suspected)
 - Positive/confirmed
- Provide for appropriate levels of patient and provider protection
- TEEs are considered high risk
 - Defer or use alternative imaging strategies if possible
 - Perform SARS-CoV-2 testing at preoperative visit, if possible
 - Proceed with TEE using precautions based on algorithm
- Institutional PPE conservation
 - Defer non-urgent exams in suspected/confirmed cases
- Limit exposure during exams
 - Problem-focused, limited examinations guided by prior studies
 - Match personnel skills to exam to minimize scan time
 - Consider use of dedicated machine for suspected/confirmed cases or high-risk units
 - Minimize both respiratory and fecal exposure during exam
- Reading room methods to reduce transmission
 - Facilitate remote report generation and echo consultation
 - Frequent disinfection of computer keyboard, mouse, surfaces, chairs, doorknobs
 - Discourage congregating in the echo lab reading room
- Identify and appropriately reassign special at-risk personnel (>60 years, chronic illness, immunocompromised, pregnancy, etc.)

Table: Fetal Cardiology Clinic Scheduling Structure during COVID-19 Outbreak

Category	Definition	Action	Examples
Low risk	<ul style="list-style-type: none"> • Low risk referral indication • Fetal anatomy scan: Normal cardiac screening exam (verified by combined experience of practitioners, or if needed by discussion w/ MFM or image review) 	<ul style="list-style-type: none"> • Cancel or do not schedule 	<ul style="list-style-type: none"> • In vitro fertilization • Gestational Diabetes • Family history of CHD (excl. exceptions noted below) • Medication exposure • Single umbilical artery • Dichorionic twins (without additional concerns)
Moderate risk	<ul style="list-style-type: none"> • Moderate/high risk referral indications when GA \geq 24 weeks • Confirmed CHD when GA < 34 weeks 	<ul style="list-style-type: none"> • Re-schedule or schedule after COVID-19 risk is decreased or GA \geq 28 weeks (consider creating a virtual “waiting list” to track patients) 	<ul style="list-style-type: none"> • 2nd opinion for CHD already identified; may schedule, consider telemedicine review of images and counseling • Fetal anatomy scan cannot confirm normal cardiac structures; may schedule but consider telemedicine review of images and counseling if needed • Pre-gestational diabetes with HgbA1C \geq8, increased NT \geq3.5, or CHD with increased recurrence in 1st degree relative (e.g. left sided obstructive lesion, heterotaxy, maternal AVSD)
High risk	<ul style="list-style-type: none"> • Urgent clinical indication • Moderate/high risk referral indication when GA < 24 weeks • Confirmed CHD when GA \geq 34 weeks 	<ul style="list-style-type: none"> • Schedule next available 	<ul style="list-style-type: none"> • Suspected CHD (any GA) • Known CHD at risk for compromise or rapid progression • Final visit for delivery planning for known CHD or 2nd opinion for CHD • Genetic/extracardiac anomaly with need to assess heart • Fetal arrhythmia (excluding isolated premature atrial contractions), new and follow-up as indicated • SSA/SSB positive mother; new visit (provide fetal heart rate home monitor if available; follow-up at GA of 20 and 26 weeks) • Fetal anatomy scan does not confirm normal cardiac structures • New monochorionic-diamniotic twin pregnancy, particularly with concern for twin-twin transfusion syndrome • Pre-gestational diabetes with HgbA1C \geq8, increased NT \geq3.5, or CHD with increased recurrence in 1st degree relative (e.g. left sided obstructive lesion, heterotaxy, maternal AVSD) • Maternal anxiety not ameliorated with telemedicine consultation
Telemedicine	<ul style="list-style-type: none"> • Remote image review • Ongoing f/u care in collaboration with MFM • Counseling 	<ul style="list-style-type: none"> • Perform as needed 	<ul style="list-style-type: none"> • Review of cardiac screening exams or fetal echocardiograms done offsite • 2nd opinion for CHD already identified with complete fetal echocardiogram available for review • Interval follow-up counseling for known CHD until \geq 34 weeks • Counseling sessions with maternal family/support off site

Resources

1. ASE COVID-19 resource page. <https://www.asecho.org/covid-19-resources/>
2. Connect@ASE COVID-19 discussion page. [https://connect.asecho.org/groups/534-Coronavirus-\(COVID-19\)](https://connect.asecho.org/groups/534-Coronavirus-(COVID-19))
3. American Institute for Ultrasound in Medicine (AIUM) guidelines for equipment disinfection. <https://www.aium.org/officialStatements/57> [aium.org]
4. Centers for Disease Control COVID-19 resource page. <https://www.cdc.gov/coronavirus/2019-nCoV/index.html>
5. Centers for Disease Control recommendations for infection prevention and control. <https://www.cdc.gov/coronavirus/2019-ncov/infection-control/control-recommendations.html>
6. Centers for Disease Control visual guide for using personal protective equipment. <https://www.cdc.gov/hai/pdfs/ppe/PPE-Sequence.pdf>
7. ISUOG Safety Committee Position Statement: Safe performance of obstetric and gynecological scans and equipment cleaning in the context of COVID-19. <https://www.isuog.org/resource/isuog-safety-committee-position-statement-safe-performance-of-obstetric-and-gynecological-scans-and-equipment-cleaning-in-the-context-of-covid-19.html>
8. The Society for Maternal Fetal Medicine COVID-19 Ultrasound Practice Suggestions. [https://s3.amazonaws.com/cdn.smfm.org/media/2272/Ultrasound_Covid19_Suggestions_\(final\)_03-24-20_\(2\)_PDF.pdf](https://s3.amazonaws.com/cdn.smfm.org/media/2272/Ultrasound_Covid19_Suggestions_(final)_03-24-20_(2)_PDF.pdf)